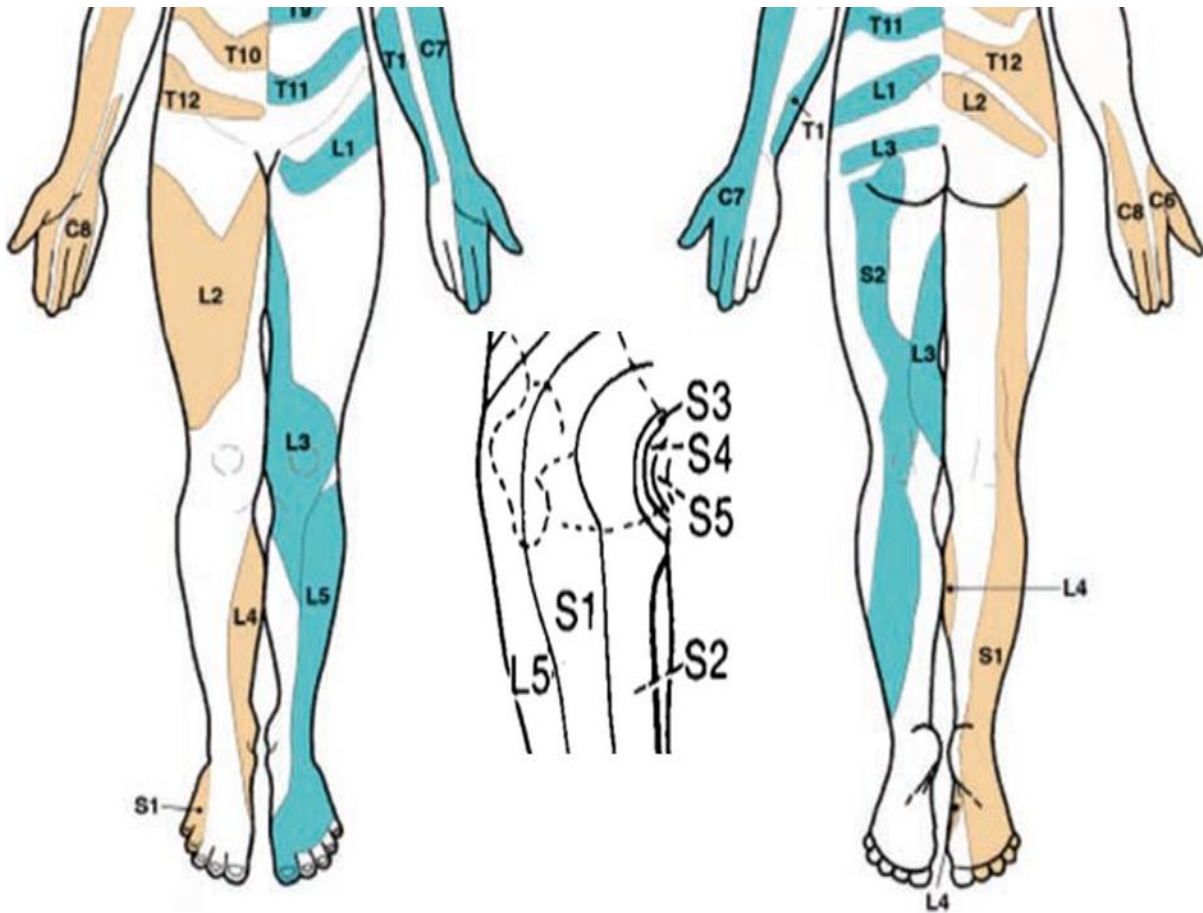


Dermatome Map to be used in conjunction with GP Assessment for Acute Low Back Pain with radicular symptoms.



³The 'evidence based' dermatome map representing the most consistent tactile dermatomal areas for each spinal dorsal nerve root found in most individuals, based on the best available evidence. The dermatomal areas shown are not autonomous zones of cutaneous sensory innervation, except across the midline where overlap is minimal, adjacent dermatomes overlap to a large and variable extent. Blank regions indicate areas of major variability and overlap. S3, S4 and S5 supply the perineum but are not shown separately (Keegan and Garrett, 1948). Note consecutive dermatomes shown in buff or blue for clarity. From Apok, Gurusinghe, Mitchell and Elmsley (2011). Neurological Sign. Dermatomes and Dogma. *Practical Neurology*. 11:100-105.